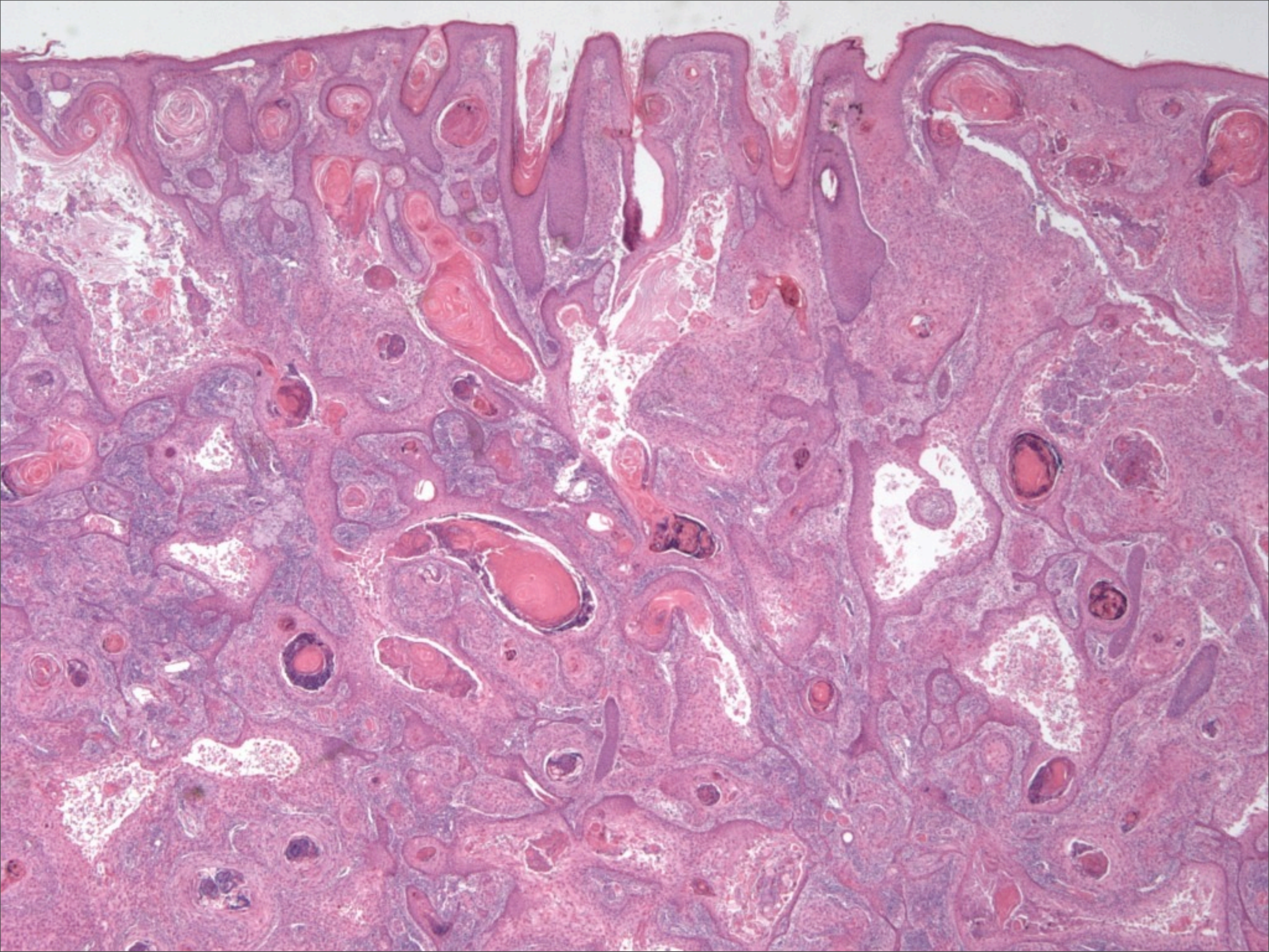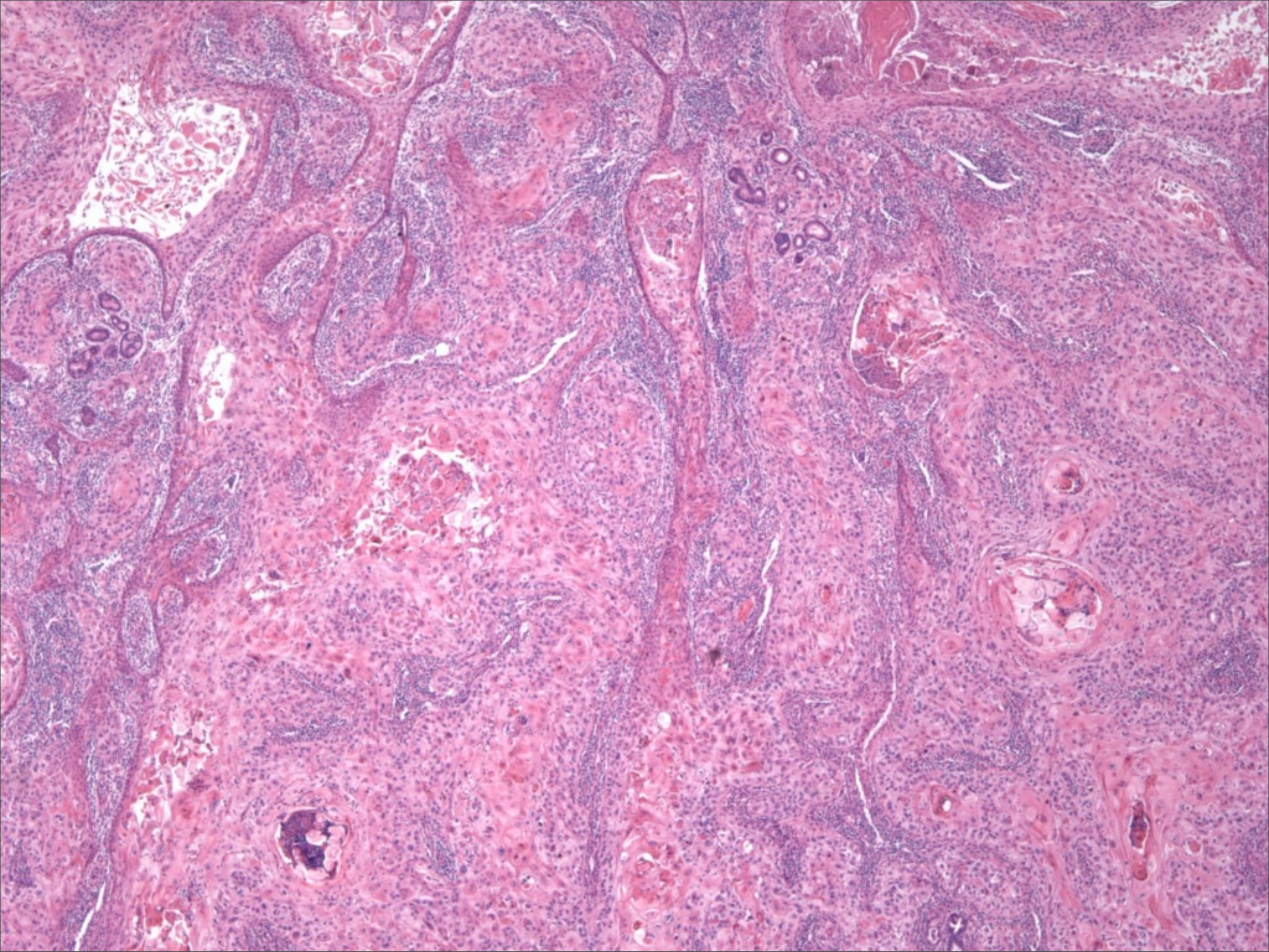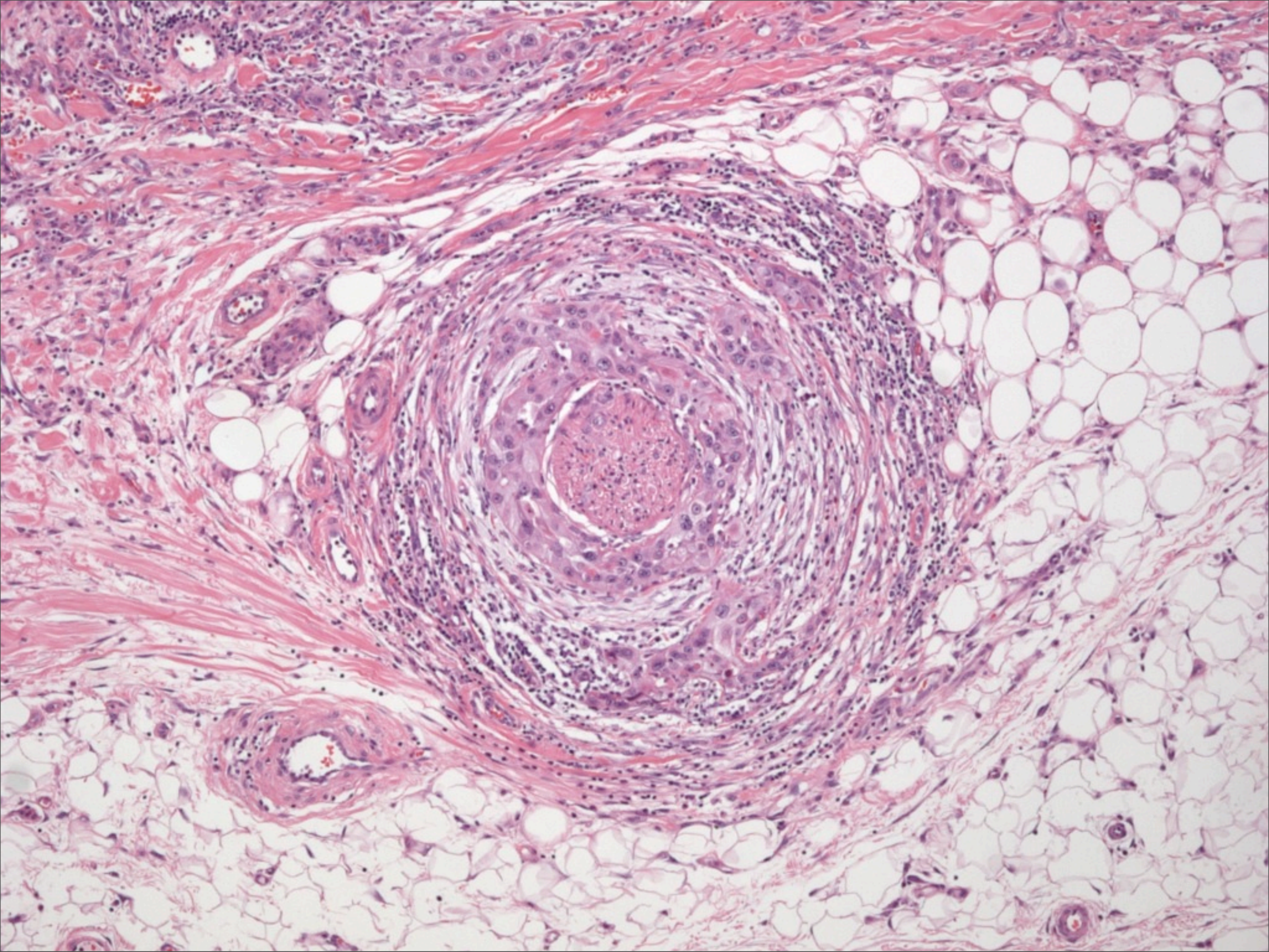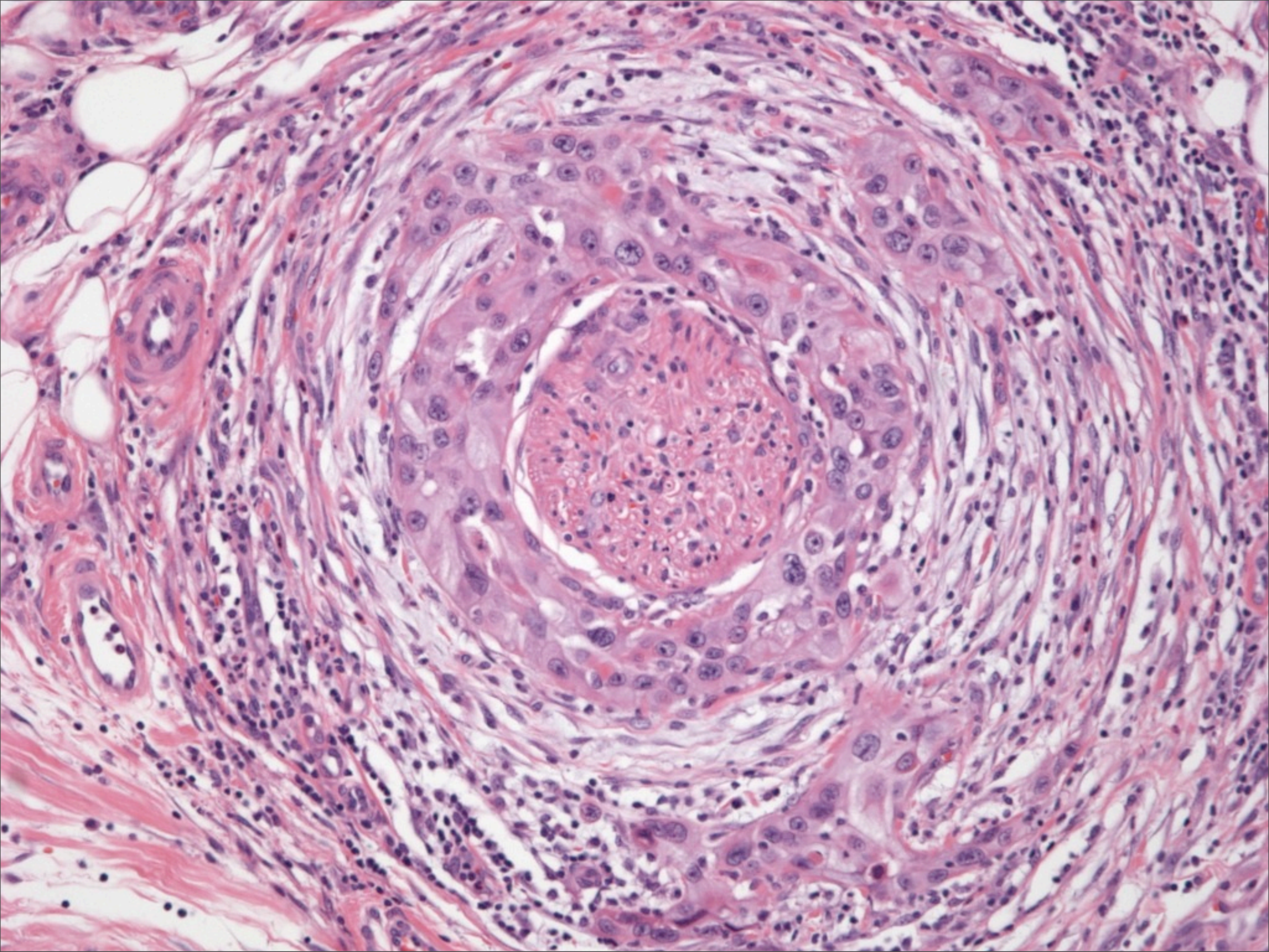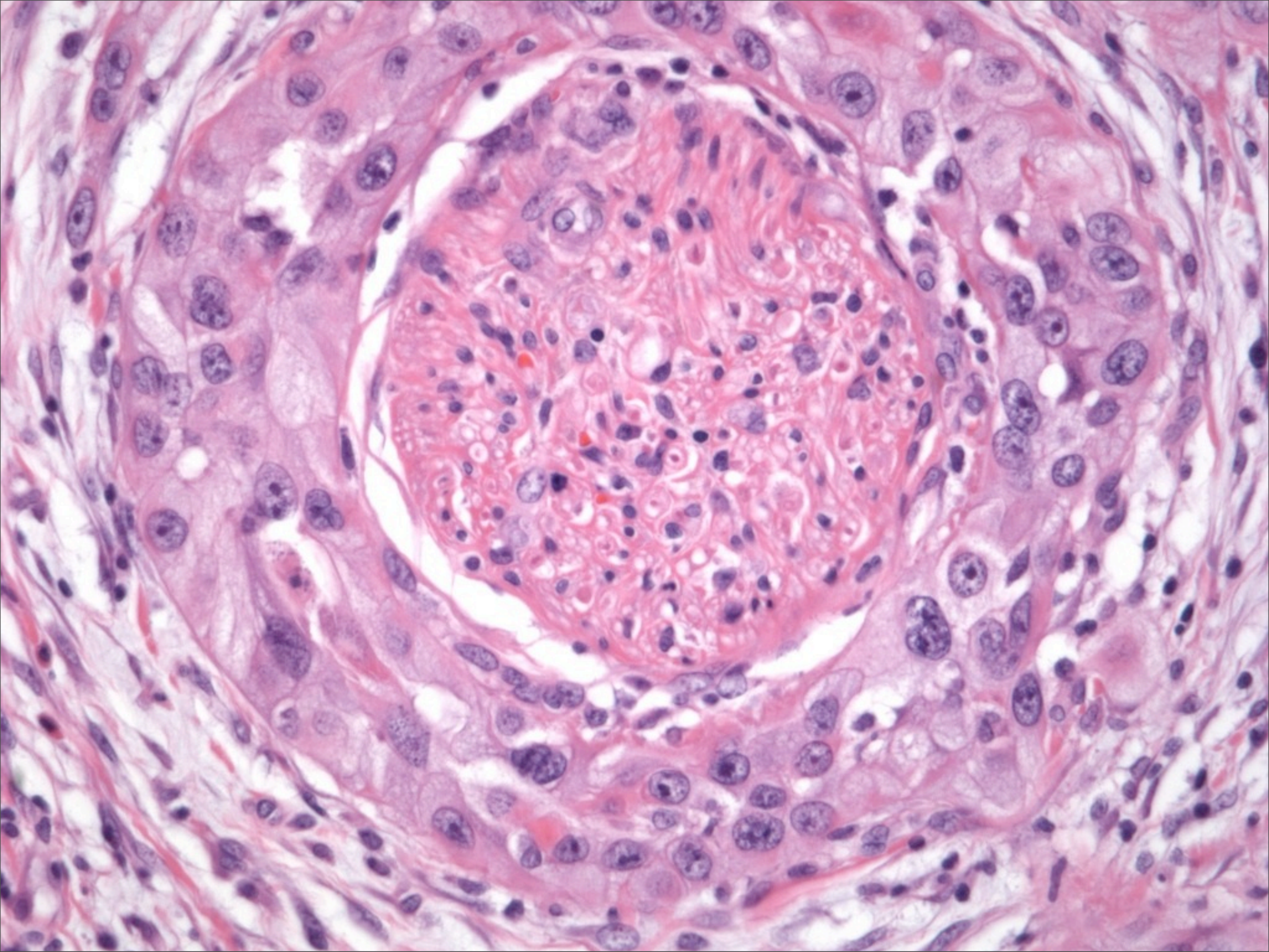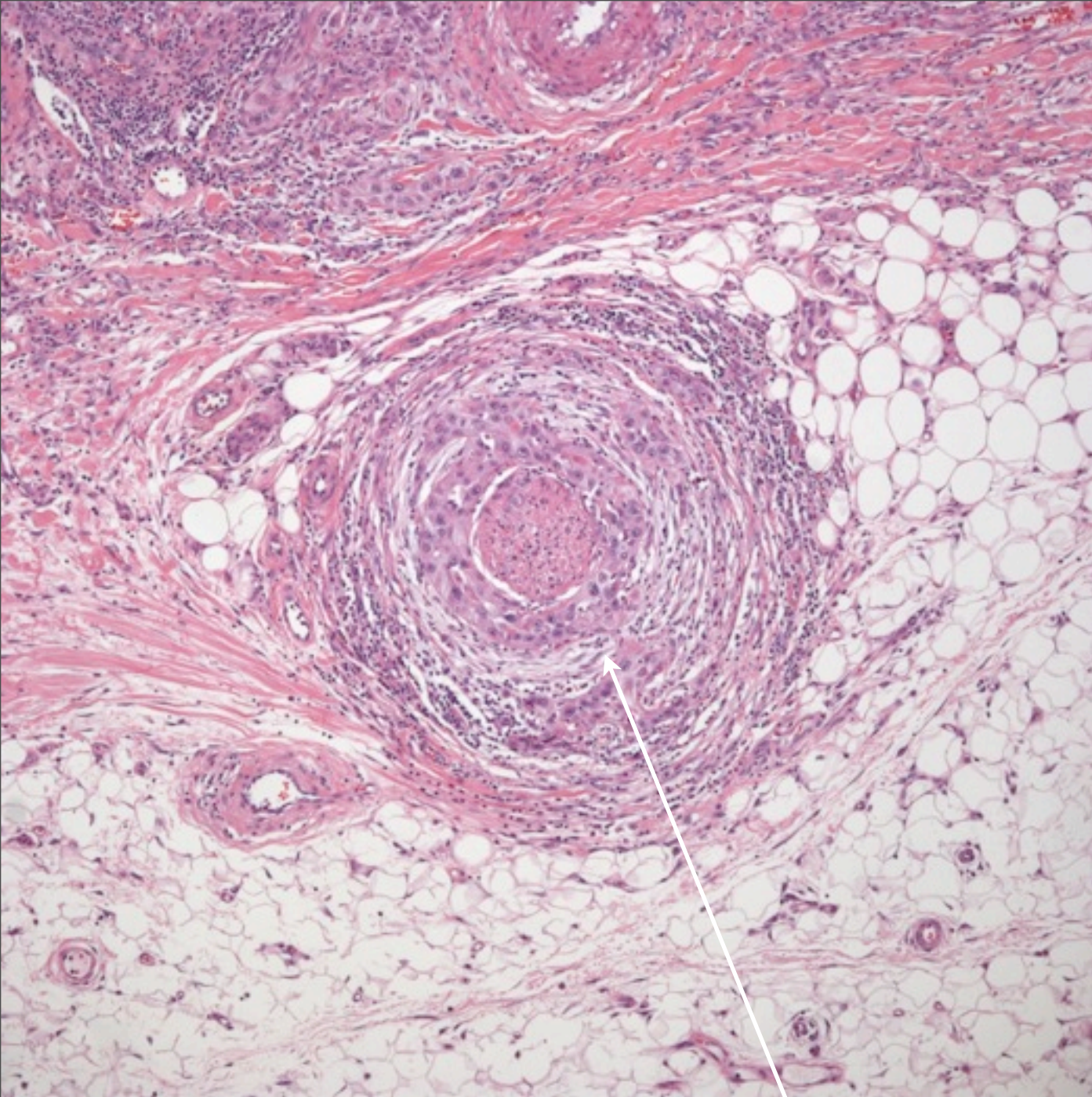


Invasive Squamous Cell Carcinoma with Perineural Invasion

Look toward base of
lesion especially
at subq fat interface



Always important to note perineural invasion

S100 may assist in difficult cases